

THORACIC DISC HERNIATIONS: TRANSTHORACIC, LATERAL, OR POSTEROLATERAL APPROACH? A REVIEW

Stefaan Mulier, M.D., and Valère Debois, M.D.

Department of Neurosurgery, St. Norbertus Hospital, Duffel, Belgium

Mulier S, Debois V. Thoracic disc herniations: transthoracic, lateral, or posterolateral approach? A review. *Surg Neurol* 1998;49:599-608.

BACKGROUND

The choice between transthoracic, lateral, and posterolateral approaches to excise thoracic disc herniations remains controversial.

METHODS

The outcome of the three approaches was compared in seven of the authors' cases and in 324 other cases reported in the literature.

RESULTS

Partial or total neurological recovery was found in 93% after a transthoracic procedure versus 87% after a posterolateral technique and 80% after a lateral approach ($p < 0.05$). A trend toward superior results after a transthoracic technique was also noted in subgroups of patients with radiculopathy, patients with intradural disc herniations, and patients with multiple lesions, although statistical significance was not reached. Pulmonary complications occurred in 7% of transthoracic techniques versus 5% in lateral and 0% in posterolateral techniques ($p < 0.025$).

CONCLUSIONS

The transthoracic approach is recommended for all thoracic disc herniations below the T4 level except for patients with serious pulmonary compromise. © 1998 by Elsevier Science Inc.

KEY WORDS

Thoracic disc herniation, transthoracic approach, posterolateral approach, lateral approach, review.

A thoracic disc herniation (TDH) is an uncommon disorder: the estimated incidence is one case per million population per year [62]. The clinical features may not be characteristic and can mistakenly be attributed to thoracic, abdominal, or

vascular pathology [7,72], resulting in a delay in diagnosis. The results of surgery greatly improved when decompressive laminectomy was abandoned and posterolateral [15,55,69], lateral [37,48], and transthoracic [21,54,61] approaches were adopted. The choice between these surgical techniques remains controversial, mainly because most reported series are small. To compare the results of these techniques we reviewed 331 cases, including 324 reported cases and 7 cases from our department.

MATERIALS AND METHODS

OUR SERIES

Between 1986 and 1993, seven patients with thoracic disc herniations had surgery in our department (Table 1). No patient had a history of trauma or Scheuermann's disease. One patient (Case 1) had previously undergone a decompressive laminectomy with only temporary improvement. All were in generally good health. The diagnosis was established using myelogram-computed tomography (MCT) studies (Fig. 1) in all cases; magnetic resonance imaging (MRI) was also used only recently in the last four individuals.

All seven patients in our series were managed with transthoracic transpleural approaches [21,63] to their thoracic disc herniations between the T3-T4 to T12-L1 levels. All discs were excised using the surgical microscope and microinstruments. Intraoperative spinal cord monitoring was not used. All TDH were extradural. Vertebral body fusions were then performed using an iliac crest autograft (Fig. 2). No external support was used. Patients were ambulated as soon as the chest tube was removed, and discharged after a median postoperative stay of 16 days. All individuals were then followed up for a median duration of 11 months.

Address reprint requests to: Dr. Valère Debois, Department of Neurosurgery, St. Norbertus Hospital, Rooienberg 25, 2570 Duffel, Belgium.

Received March 16, 1995; accepted September 2, 1997.

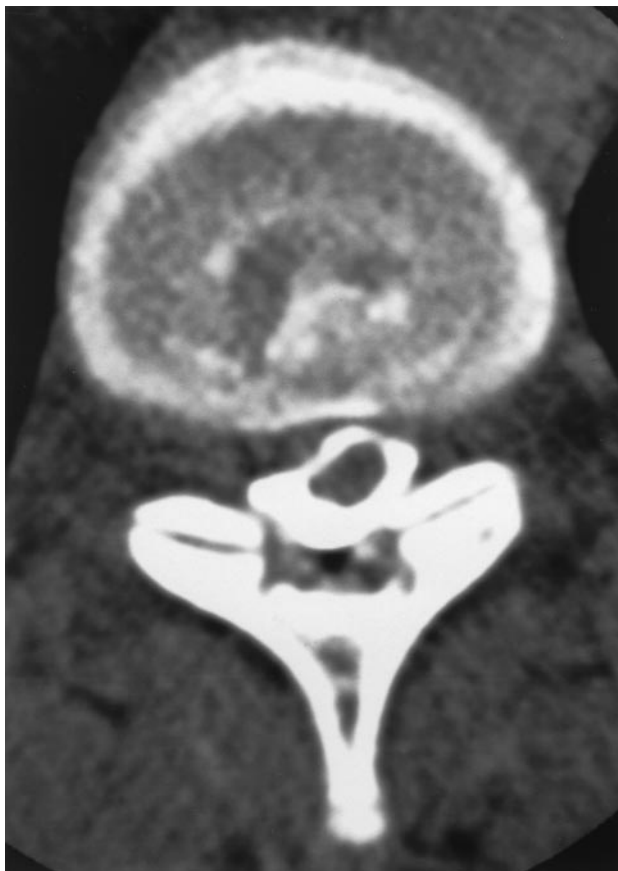
1 Clinical Data Before and After Surgery

CASE	1	2	3	4	5	6	7
Age, Sex	47 F	32 M	41 M	57 M	50 M	37 M	41 F
TDH							
Level	9-10	9-10	9-10	3-4	12-1	11-12	10-11
Location	centr	L lat	L c.lat	R c.lat	L c.lat	centr	R lat
Calcification	+	-	+	-	-	-	-
Symptoms							
Duration	2 y	1 y	1.5 y	1 y	2 y	4 y	2 y
Paresis	mild	none	mild	mild	mild	mild	mild
Bladder dysfunction	+	+	-	-	-	-	-
Radicular pain	-	left	bilat	-	-	-	-
Back pain	+	+	-	+	-	-	-
Result	I	A	U	I	I	I	I

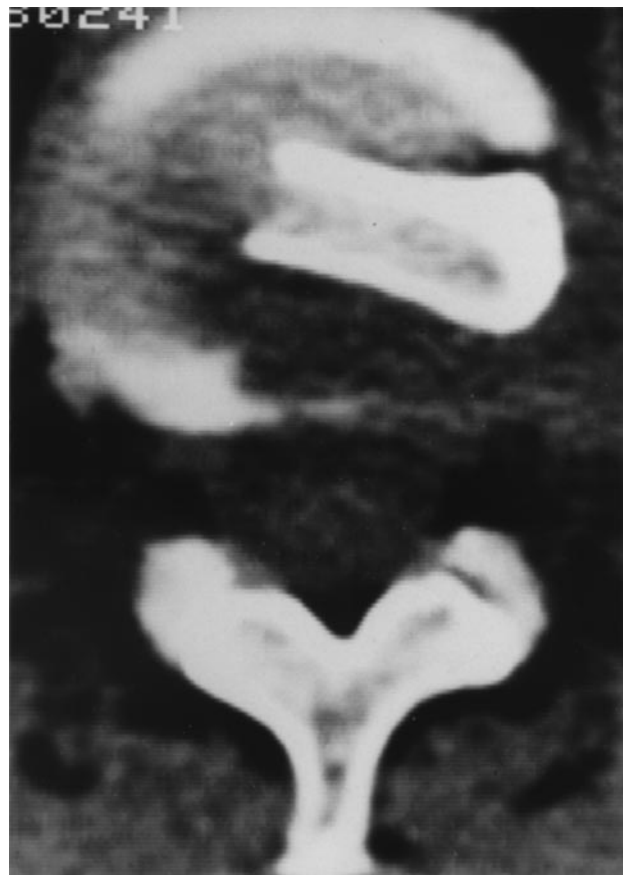A, asymptomatic; I, improved; U, unchanged; TDH, thoracic disc herniation.

Of the seven patients in our series, one became asymptomatic, five improved, and one remained unchanged. Four patients had residual pain at the thoracotomy site. One patient had a transient hypoesthesia of the lateral side of the thigh because of

operative positioning resulting in compression of the lateral cutaneous femoral nerve. One patient underwent a transurethral prostatectomy for postoperative urinary retention. There were no respiratory complications. Postoperative plain radio-



1 Myelogram-computed tomography showing right centrolateral TDH at level T10-T11 with displacement of the cord to the left (Case 7).



2 Postoperative computed tomography showing that the posterolateral disc quadrant at level T12-L1 has been removed and an iliac crest bone graft has been placed (Case 5).

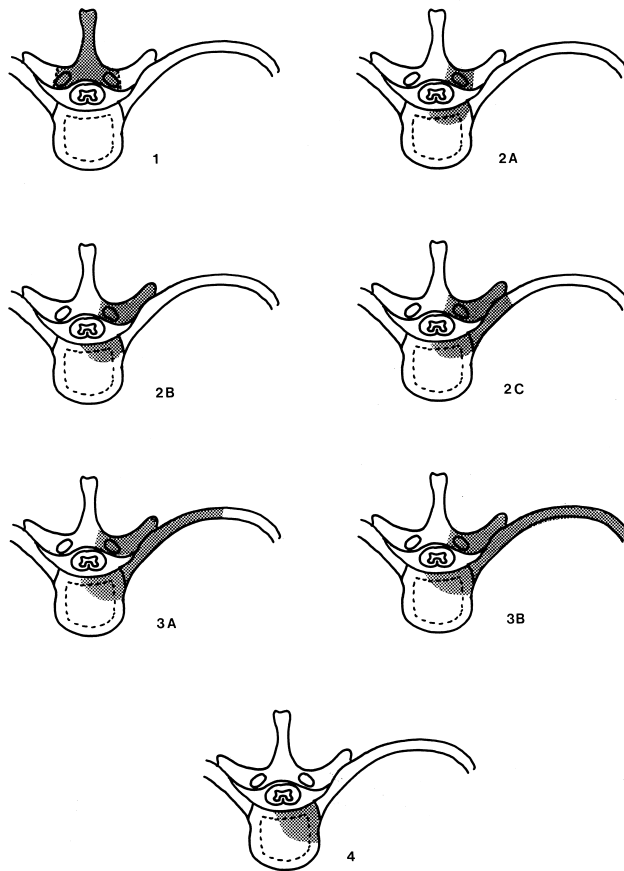
2 Scoring of Lower Extremity Paresis

None	Intact motor function
Mild	Mild impairment, independent ambulation
Moderate	Ambulation with external support
Severe	Slight movement, nonambulatory
Complete	No movement

graphs of the spine showed no signs of vertebral collapse or displacement.

REPORTED CASES

Thoracic disc herniations reported in the literature, managed by the posterolateral, lateral and transthoracic approaches, were reviewed. The duration of symptoms was assessed, recent being defined as up to 1 year, and longstanding as over 1 year. A history of previous thoracic disc surgery was noted. Paresis was graded according to Maiman's classification [48] (Table 2), and the presence of radiculopathy and sphincteric dysfunction was looked at. Disc characteristics such as level, multiplicity, location (central if it was exactly on the midline, lateral if the prolapse projected lateral to the lateral aspect of the thecal sac, and centrolateral), calcification, and extension through the dura, were determined. Figure 3 and Table 3 show the classification of the different surgical approaches [25,72] and Table 4 shows the five categories of



3 Diagram showing the parts that are resected in the various techniques: 1) laminectomy; 2a) transpedicular and transfacetal approach, 2b) transversoarthropediclectomy; 2c) costotransversectomy; 3a) lateral rhachotomy; 3b) lateral extracavitary approach; and 4) transthoracic approach.

3 Reported Cases

TECHNIQUE	NUMBER OF CASES	REFERENCES
Posterior approach: laminectomy	0	
Posterolateral approaches:		
Transpedicular approach:	42	7, 10, 27, 28, 31, 34, 44, 46, 55
Transfacetal approach:	6	70
Transversoarthropediclectomy:	35	15, 30, 46, 67, 75
Costotransversectomy:	79	1, 3, 6, 8, 13, 18, 22, 27, 33, 35, 36, 39, 41, 42, 46, 50, 53, 59, 68, 69, 70, 73, 74, 78, 79
Lateral approaches:		
Lateral rhachotomy:	16	5, 14, 16, 17, 37
Lateral extracavitary approach:	45	23, 48, 49, 77
Transthoracic approaches:		
Transpleural thoracotomy:	76	1, 2, 4, 7, 8, 9, 11, 12, 13, 14, 19, 20, 21, 24, 27, 29, 30, 31, 32, 38, 40, 43, 46, 51, 52, 56, 57, 58, 59, 60, 65, 66, 76, 78
Extrapleural thoracotomy:	23	54
Thoracoscopy:	1	61
Total:	324	

4 Scoring of Neurological Outcome

Asymptomatic (A)	No impediment to normal work and social activities, although minor neurological abnormalities (e.g. hyperreflexia) may be present on examination
Improved (I)	Improvement from previous neurological state, although not normal
Unchanged (U)	No alteration in neurological state
Worse (W)	Deterioration in neurological state
Dead (D)	Attributable to postoperative complications
Success (S)	Asymptomatic or improved
Failure (F)	Unchanged, worse, or dead

neurological outcome [62]. Complications were noted. The χ^2 test was used for statistical analysis.

RESULTS

Our analysis of 331 cases included assessment of 7 patients from our department and review of 324 other cases from the literature. Recent herniations (≤ 1 year) had a median duration of 4 months (range, 1 day-1 year), as compared with longstanding herniations (> 1 year) that had a median duration of 3 years (range, 1 year-24 years). The presence ($p < 0.01$) and degree ($p < 0.001$) of preoperative paresis, the absence of preoperative radiculopathy ($p < 0.001$), the duration of symptoms ($p < 0.001$), and a history of previous surgery ($p < 0.05$) had statistically significant negative effects on neurological recovery (Table 6). Alterna-

tively, outcome remained unaffected by the location or level of a disc, by multiplicity of discs, and by the presence of calcification or intradural penetration.

As would be anticipated, the lateral location of a disc correlated well with the presence of radiculopathy ($p < 0.001$) and a central or centrolateral location of a disc with the presence of paresis ($p < 0.001$). Partial or total neurological recovery was found in 93% after a transthoracic procedure versus 87% after a posterolateral technique and 80% after a lateral approach ($p < 0.05$) (Table 8). These superior results for the transthoracic approach were obtained in spite of a significantly higher proportion of patients with paresis and a lower proportion of patients with radiculopathy (Table 7). In the analysis of subgroups, lateral techniques could not be evaluated because there were too few patients. A trend toward a better neurological outcome after transthoracic techniques than after posterolateral techniques was also noted in subgroups of patients with radiculopathy, patients with intradural disc herniations, and patients with multiple lesions; although statistical significance was not reached (Table 8).

Twenty patients underwent a secondary intervention. A laminectomy was performed as the first procedure in 11 cases. In four cases, originally managed by a posterolateral approach, the thoracic disc herniation was incompletely removed. In two more cases after a posterolateral approach, the disc herniation recurred at the same level. In one case, surgery was performed at a wrong level. In another case, only a Harrington rod was placed. Lastly, one patient developed a new disc herniation at another level. As secondary procedure, a transthoracic approach was used in nine patients, a posterolateral approach in five patients, and a lateral

5 Characteristics of TDH

Duration of symptoms	≤ 1 year:	59% (109)	> 1 year:	41% (75)	n:184
Previous surgery	yes:	6% (20)	no:	94% (311)	n:331
Paresis	present:	79% (262)	absent:	21% (69)	n:331
Degree of paresis	none:	21% (69)			
	mild:	37% (118)	moderate:	25% (79)	
	severe:	13% (43)	complete:	4% (12)	n:321
Sphincter dysfunction	present:	39% (99)	absent:	61% (155)	n:254
Radiculopathy	present:	32% (82)	absent:	68% (173)	n:255
Level	$\leq T4-T5$:	5% (15)	$> T4-T5$:	95% (316)	n:331
Multiplicity	multiple:	7% (22)	single:	93% (309)	n:331
Location	central(c):	28% (61)	c.lateral:	19% (41)	
	c. or c.lat.:	36% (79)	lateral:	17% (37)	n:218
Calcification	present:	41% (90)	absent:	59% (130)	n:220
Intradural penetration	present:	10% (20)	absent:	90% (182)	n:201
Scheuermann's	present:	5% (16)	absent:	95% (276)	n:292

n, number of evaluable cases.

6 Factors Influencing Outcome

	ASYMPTOMATIC	IMPROVED	FAILURE	TOTAL
Paresis				
Absent	64% (44)	30% (21)	6% (4)	100% (69)
Present	42% (111)	44% (114)	14% (37)	100% (262)
<i>p</i> < 0.01				n = 331
Radiculopathy				
Absent	41% (71)	45% (78)	14% (24)	100% (173)
Present	72% (59)	24% (20)	4% (3)	100% (82)
<i>p</i> < 0.001				n = 255
Duration of symptoms				
≤1 year	57% (62)	34% (37)	9% (10)	100% (109)
>1 year	29% (22)	59% (44)	12% (9)	100% (75)
<i>p</i> < 0.001				n = 184
Number of procedures				
Primary	49% (151)	39% (122)	12% (38)	100% (311)
Secondary	20% (4)	65% (13)	15% (3)	100% (20)
<i>p</i> < 0.05				n = 331

n, number of evaluable cases.

approach in three patients. Success after these secondary procedures was achieved in 17 of 20 cases: 4 patients became asymptomatic and 13 improved. The three secondary failures were all noted after the secondary lateral procedures.

Pulmonary complications occurred in 7% of transthoracic techniques versus 5% in lateral and 0% in posterolateral techniques (*p* < 0.025).

DISCUSSION

In a retrospective review of 331 patients having surgery for thoracic disc herniations, factors determining neurological outcome were analyzed. Cord damage seemed to be more permanent than root injury, with less severe pareses appearing more reversible than more severe plegias. The nature of the neurological impairment (paresis versus radiculopathy) had a stronger predictive value than the central or lateral location of the herniation. Patients with a longer duration of symptoms had a worse prognosis, which underlines the need for early diagnosis and prompt surgery. The better results of transthoracic techniques compared with lateral

and posterolateral techniques may be explained by the different angle of approach to the spinal canal. The thoracic spinal canal, in contrast to the cervical and lumbar canal, is smaller and more difficult to enter and explore surgically. Because of the poor vascular supply to the thoracic spinal cord [26], even minor manipulation may cause severe injury and must be prevented. In the transpedicular [55] and in the transfacetial [70] technique, the approach to the spinal canal is slightly oblique and the visibility of the midline is limited [27,45,48,64,72,79]. To improve the exposure, resection of the transverse processes is added in the transversoarthropediclectomy [15], and resection of the adjacent medial portion of the rib in the costotransversectomy [69]. The lateral rhachotomy [37] and the lateral extracavitary approach [48] provide a more lateral route. The anterolateral transthoracic approach [21,54,61] allows for the best exposure, while providing for the safest and most complete spinal cord decompression. Many authors now agree that central herniations are best treated by the transthoracic route, but there is still some reluctance to apply this approach for the excision of lateral her-

7 Comparability Between Treatment Groups

	TRANSTHORACIC	POSTEROLATERAL	LATERAL	N	P
Paresis	87% (93/107)	70% (114/163)	90% (55/61)	331	<0.001
Radiculopathy	20% (20/99)	42% (58/138)	22% (4/18)	255	<0.01
Duration > 1 y	39% (37/95)	44% (35/79)	30% (3/10)	184	NS
Secondary	8% (9/107)	3% (5/163)	10% (6/61)	331	NS

n, number of evaluable cases.

8 Outcome According to Technique

	ASYMPTOMATIC	IMPROVED	FAILURE	TOTAL
All TDH				
Transthoracic	52% (56)	40% (43)	7% (8)	100% (107)
Posterolateral	49% (80)	38% (62)	13% (21)	100% (163)
Lateral	31% (19)	49% (30)	20% (12)	100% (61)
$p < 0.05$				n = 331
TDH with radiculopathy				
Transthoracic	90% (18)	5% (1)	5% (1)	100% (20)
Posterolateral	67% (39)	29% (17)	3% (2)	100% (58)
NS				n = 78
Intradural TDH				
Transthoracic	33% (2)	67% (4)	0% (0)	100% (6)
Posterolateral	23% (3)	46% (6)	31% (4)	100% (13)
NS				n = 19
Multiple TDH				
Transthoracic	88% (7)	13% (1)	0% (0)	100% (8)
Posterolateral	50% (7)	43% (6)	7% (1)	100% (14)
NS				n = 22

n, number of evaluable cases.

nations [27,71]. However, in our analysis, a clear trend toward a more complete neurological recovery was found in patients with radiculopathy. The fact that statistical significance was not reached in this subgroup was probably because of low numbers (β -error). Pulmonary complications such as pneumothorax, pleuraeffusion, chylothorax, atelectasis, and prolonged ventilation occurred only in 7% after a transthoracic technique. These complications are usually transient and do not outweigh the advantage of improved neurological outcomes. The posterolateral approach is indicated only in patients with serious pulmonary compromise, who would not withstand a thoracotomy. However, in these patients in poor general condition, one must consider performing no surgery, as any approach will have an increased morbidity. The transthoracic route is recommended to excise intradural herniations as well as multiple herniations as a trend toward better results after this technique was noted. Thoracic disc herniations occurring between T1-T4 levels were best approached, if lateral, through the pedicle, or, if anterior, through the sternum [27,47,66,67,72].

Although the results of secondary procedures are not as good as those for primary operations, success was achieved in 17 of 20 (85%) reoperations. These data indicate that suboptimal results after first procedures should be re-evaluated with myelo-CT studies to determine the presence of residual or new pathology. Indeed, the documentation of retained, residual, and newly occurring discs found in this series strongly supports this aggres-

sive approach to patients considered initial operative failures.

CONCLUSIONS

Operative results after transthoracic procedures are better compared with those encountered after lateral and posterolateral approaches. Transient pulmonary complications occur in 7% of cases. The transthoracic approach is recommended for all thoracic disc herniations below T4 except for patients with serious pulmonary compromise. The presence and degree of preoperative paresis have a negative impact on outcome of surgery, whereas the presence of radiculopathy has a positive effect on outcome. Early diagnosis and treatment offer better chances for postoperative neurological improvement. Patients with suboptimal results after surgery should be reevaluated for residual disc herniation as success may follow secondary surgery in 85% of cases.

The authors thank Mr. Johan De Leersnyder, M.D., who performed the thoracotomies; Mr. William A. Wagle, M.D., and Mrs. Griet Van Buggenhout, MD, for reviewing the manuscript; and Mrs. Dominique Vanstiphout and Mr. Hans van de Noort, for secretarial assistance.

REFERENCES

1. Albrand OW, Corkill G. Thoracic disc herniation: treatment and prognosis. *Spine* 1979;4:41-6.
2. Al-Rajeh S, Chowdhary UM, Al-Freih H, Al-Mohanna F. Thoracic disc protrusion and situs inversus in Klippel-Feil Syndrome. *Spine* 1990;15:1379-81.

3. Arce CA, Dohrmann GJ. Thoracic disc herniation. Improved diagnosis with computed tomographic scanning and a review of the literature. *Surg Neurol* 1985; 23:356-61.
4. Bartlett GR, Robertson PA. Acute thoracic disc prolapse with paraparesis following a rugby tackle: a case report. *N Z Med J* 1994;107:86-7.
5. Benson MKD, Byrnes DP. The clinical syndromes and surgical treatment of thoracic intervertebral disc prolapse. *J Bone Jt Surg* 1975;57:471-7.
6. Bhole R, Gilmer RE. Two-level thoracic disc herniation. *Clin Orthop Rel Res* 1984;190:129-31.
7. Blumenkopf B. Thoracic intervertebral disc herniations: diagnostic value of magnetic resonance imaging. *Neurosurgery* 1988;23:36-40.
8. Bohlman HH, Zdeblick TA. Anterior excision of herniated thoracic discs. *J Bone Jt Surg* 1988;70A:1038-47.
9. Boriani S, Biagini R, De Iure F, Rocella P, Veronesi V, Dalbuono S, Di Fiore M. Two-level thoracic disc herniation. *Spine* 1994;19:2461-6.
10. Bouchez B, Arnott G, Combelles G, Pruvo JP. Compression médullaire par hernie discale dorsale. Une complication de la maladie de Scheuermann. *Rev Neurol (Paris)* 1986;142:154-8.
11. Brennan M, Perrin JCS, Canady A, Wesolowski D. Paraparesis in a child with a herniated thoracic disc. *Arch Phys Med Rehabil* 1987;68:806-8.
12. Brown CW, Deffer PA, Akmajian J, Donaldson DH, Brugman JL. The natural history of thoracic disc herniation. *Spine* 1992;17 suppl:97-102.
13. Bury RW, Powell T. Prolapsed thoracic intervertebral disc. The importance of CT assisted myelography. *Clin Radiol* 1989;40:416-21.
14. Caron JP, Djindjian R, Julian H, Lebrigand H, Houdart R, Comoy J. Les hernies discales dorsales. Les modalités de leur retentissement de la moelle, leur traitement chirurgical par abord latéral ou postéro-latéral, avec exérèse de la saillie discale. *Ann Med Interne (Paris)* 1971;122:675-88.
15. Carson J, Gumpert J, Jefferson A. Diagnosis and treatment of thoracic intervertebral disc protrusions. *J Neurol Neurosurg Psychiat* 1971;34:68-77.
16. Chesterman PJ. Spastic paraplegia caused by sequestered thoracic intervertebral disc. *Proc R Soc Med* 1964;57:87-8.
17. Chou SN, Seljeskog EL. Alternative surgical approaches to the thoracic spine. *Clin Neurosurg* 1973; 20:306-21.
18. Chowdhary UM. Intradural thoracic disc protrusion. *Spine* 1978;12:718-9.
19. Coleman RJ, Hamlyn PJ, Butler P. Anterior spinal surgery for multiple thoracic disc herniations. *Br J Neurosurg* 1990;4:541-3.
20. Coscia MF, Strate RW. Calcified thoracic disc herniation with paraparesis. A case report. *Acta Orthop Scand* 1993;64:489-90.
21. Crafoord C, Hiertonn T, Lindblom K, Olsson SE. Spinal cord compression caused by a protruded thoracic disc. Report of a case treated with antero-lateral fenestration of the disc. *Acta Orthop Scand* 1958;28: 103-7.
22. Davies PR, Kaar G. High thoracic disc prolapse in a rugby player: the first reported case. *Br J Sports Med* 1993;27:177-8.
23. Delfini R, Di Lorenzo N, Ciapetta P, Bristot R, Cantore G. Surgical treatment of thoracic disc herniation: a reappraisal of Larson's lateral extracavitary approach. *Surg Neurol* 1996;45:517-23.
24. de Tribolet N, Schnyder P, Livio JJ, Boumghar M. L'abord transthoracique des hernies discales dorsales. *Neurochirurgie* 1982;28:187-93.
25. Dohn DF. Thoracic spinal cord decompression: alternative surgical approaches and basis of choice. *Clin Neurosurg* 1980;27:611-23.
26. Domisse GF. The blood supply of the spinal cord. *J Bone Jt Surg* 1974;56B:225-35.
27. El-Kalliny M, Tew JM, van Loveren H, Dunsker S. Surgical approaches to thoracic disc herniations. *Acta Neurochir (Wien)* 1991;111:22-3.
28. Epstein NE, Syrquin MS, Epstein JA, Decker RE. Intradural disc herniations in the cervical, thoracic and lumbar spine: report of three cases and review of the literature. *J Spinal Disord* 1990;3:396-403.
29. Fidler MW, Goedhart ZD. Excision of prolapse of thoracic intervertebral disc. A transthoracic technique. *J Bone Jt Surg* 1984;66B:518-22.
30. Fouquet B, Goupille P, Jan M, Lapierre F, Burdin P, Valat JP. Hernies discales thoraciques. *Rev Rhum Mal Osteoartic* 1988;55:123-6.
31. Francavilla TL, Powers A, Dina T, Rizzoli HV. MR imaging of thoracic disk herniations. *J Comput Assist Tomogr* 1987;11:1062-5.
32. Galtier B, Irthum B, Ristori JM, Bussièrre JL, Rampon S. Hernies discales dorsales. A propos de six observations. *Revue de la littérature. Rev Rhum Mal Osteoartic* 1987;54:737-44.
33. Garrido E. Modified costotransversectomy: a surgical approach to ventrally placed lesions in the thoracic spinal canal. *Surg Neurol* 1980;13:109-12.
34. Hamilton MG, Thomas HG. Intradural herniation of a thoracic disc presenting as flaccid paraplegia: case report. *Neurosurgery* 1990;27:482-4.
35. Hochman MS, Pena C, Ramirez R. Calcified herniated thoracic disc diagnosed by computerized tomography. *J Neurosurg* 1980;52:722-3.
36. Hufnagel A, Zierski J, Agnoli L, Schütz HJ. Claudicatio spinalis durch thorakalen Bandscheibenvorfall. *Nervenarzt* 1988;59:419-21.
37. Hulme A. The surgical approach to thoracic intervertebral disc protrusions. *J Neurol Neurosurg Psychiat* 1960;23:133-7.
38. Ikegawa S, Nakamura K, Hoshino Y, Shiba M. Thoracic disc herniation in spondyloepiphyseal dysplasia. A report on two cases. *Acta Orthop Scand* 1993;64: 105-6.
39. Jamieson DRS, Ballantyne JP. Unique presentation of a prolapsed thoracic disk: Lhermitte's symptom in a golf player. *Neurology* 1995;45:1219-21.
40. Klein DM, Weiss RL, Allen JE. Scheuermann's dorsal kyphosis and spinal cord compression: case report. *Neurosurgery* 1986;18:628-31.
41. Kumar A. Thoracic disc prolapse in calcified discs. *Orthopedics* 1991;14:98-9.
42. Lanska DJ, Lanska MJ, Fenstermaker R, Selman W, Mapstone T. Thoracic disk herniation associated with chiropractic spinal manipulation. *Arch Neurol* 1987; 44:996-7.
43. Lehman LB. Paraparesis during myelography associated with a ruptured thoracic intervertebral disc. *Neurosurgery* 1989;24:912-4.

44. Le Roux PD, Haglund MM, Harris AB. Thoracic disc disease: experience with the transpedicular approach in twenty consecutive patients. *Neurosurgery* 1993;33:58-66.
45. Lesoin F, Jomin M. Posterolateral approach to thoracic disk herniations through transversarthropediclectomy. *Surg Neurol* 1985;23:375-9.
46. Lesoin F, Rousseaux M, Autricque A, Reesaul Y, Vilette L, Clarisse J, Jomin M. Thoracic disc herniations: evolution in the approach and indications. *Acta Neurochir (Wien)* 1986;80:30-4.
47. Lobosky JM, Hitchon PW, Mc Donnel DE. Transthoracic anterolateral decompression for thoracic spinal lesions. *Neurosurgery* 1984;14:26-30.
48. Maiman DJ, Larson SJ, Luck E, El Ghatit A. Lateral extracavitary approach to the spine for thoracic disc herniation: report of 23 cases. *Neurosurgery* 1984;14:178-82.
49. Maiman DJ, Daniels D, Larson SJ. Magnetic resonance imaging in the diagnosis of lower thoracic disc herniation. *J Spinal Disord* 1988;1:134-8.
50. Michowiz SD, Rappaport HZ, Shaked I, Yellin A, Sahar A. Thoracic disc herniation associated with papilledema. Case report. *J Neurosurg* 1984;61:1132-4.
51. Morgenlander JC, Massey EW. Neurogenic claudication with positionally dependent weakness from a thoracic disc herniation. *Neurology* 1989;39:1133-4.
52. Nakayama H, Hashimoto H, Hase H, Hirasawa Y, Suzuki M. An 80-year-old patient with thoracic disc herniation. *Spine* 1990;15:1234-5.
53. Oppenheim JS, Rothman AS, Sachdev VP. Thoracic herniated discs: review of the literature and 12 cases. *Mount Sinai J Med* 1993;60:321-6.
54. Otani K, Yoshida M, Fujii E, Nakai S, Shibasaki K. Thoracic disc herniation. Surgical treatment in 23 patients. *Spine* 1988;13:1262-7.
55. Patterson RH, Arbit E. A surgical approach through the pedicle to protruded thoracic discs. *J Neurosurg* 1978;48:768-72.
56. Perot PL, Munro DD. Transthoracic removal of midline thoracic disc protrusions causing spinal cord compression. *J Neurosurg* 1969;31:452-8.
57. Quast LM. Thoracic disc disease: diagnosis and surgical treatment. *J Neurosci Nurs* 1987;19:198-204.
58. Ransohoff J, Spencer F, Siew F, Gage L. Transthoracic removal of thoracic disc. Report of three cases. *J Neurosurg* 1969;31:459-61.
59. Reif J, Gilsbach J, Ostheim-Dzerowycz W. Differential diagnosis and therapy of herniated thoracic discs. Discussion of six cases. *Acta Neurochir (Wien)* 1983;67:255-65.
60. Roosen N, Dietrich U, Nicola N, Irlich G, Gahlen D, Stork W. MR imaging of calcified herniated thoracic disk. Case report. *J Comput Assist Tomogr* 1987;11:733-5.
61. Rosenthal D, Rosenthal R, de Simone A. Removal of a protruded thoracic disc using microsurgical endoscopy. A new technique. *Spine* 1994;19:1087-91.
62. Russel T: Thoracic intervertebral disc protrusion: experience of 67 cases and review of the literature. *Br J Neurosurg* 1989;3:153-60.
63. Safdari H, Baker RL. Microsurgical anatomy and related techniques to an anterolateral transthoracic approach to thoracic disc herniations. *Surg Neurol* 1985;23:589-93.
64. Sekhar LN, Jannetta PJ. Thoracic disc herniation: operative approaches and results. *Neurosurgery* 1983;12:303-5.
65. Severi P, Ruelle A, Andrioli G. Multiple calcified thoracic disc herniations. A case report. *Spine* 1992;17:449-51.
66. Shikata J, Yamamuro T, Iida H, Kashiwagi N. Multiple thoracic disc herniations: case report. *Neurosurgery* 1988;22:1068-70.
67. Signorini G, Baldini M, Vivenza C, Prici L, Tonnarelli GP. Surgical treatment of thoracic disc protrusion. *Acta Neurochir (Wien)* 1979;49:245-54.
68. Simon JN, Martz DG, Mokriski BK, Keene CL, Gillies BS, Malinow AM. Spinal cord compression following labor and delivery with epidural analgesia. *Reg Anesth* 1989;14:256-8.
69. Simeone FA. The modern treatment of thoracic disc disease. *Orthop Clin North Am* 1971;2:453-62.
70. Simpson JM, Silveri CP, Simeone FA, Balderston RA, An HS. Thoracic disc herniation. Re-evaluation of the posterior approach using a modified costotransversectomy. *Spine* 1993;18:1872-7.
71. Stillerman CB, Chen TC, Diaz Day J, Couldwell WT, Weiss MH. The transfacet pedicle-sparing approach for thoracic disc removal: cadaveric morphometric analysis and preliminary clinical experience. *J Neurosurg* 1995;83:971-6.
72. Stillerman CB, Weiss MH. Management of thoracic disc disease. *Clin Neurosurg* 1992;38:325-52.
73. Stone JL, Lichtor T, Banerjee S. Intradural thoracic disc herniation. *Spine* 1994;19:1281-4.
74. Tahmouresie A. Herniated thoracic intervertebral disc—an unusual presentation: case report. *Neurosurgery* 1980;7:623-5.
75. Tanaka S, Satoh S, Sasaki T, Umemori T, Iida T. (Lower thoracic disc herniation with acutely developed vesicorectal dysfunction: case report). *No Shinkei Geka* 1993;21:633-637 (Japanese, English abstract).
76. Weiss MH, Heiden JS, Apuzzo MLJ, Kurze T. Anterior decompression of the thoracic and thoracolumbar spine. *Bull Los Angeles Neurol Sci* 1975;40:112-5.
77. Whitcomb DC, Martin SP, Schoen RE, Jho HD. Chronic abdominal pain caused by thoracic disc herniation. *Am J Gastroenterol* 1995;90:835-7.
78. Yablon JS, Kasdon DL, Levine H. Thoracic cord compression in Scheuermann's disease. *Spine* 1988;13:896-8.
79. Young S, Karr G, O'Laoire SA. Spinal cord compression due to thoracic disc herniation: results of microsurgical posterolateral costotransversectomy. *Br J Neurosurg* 1989;3:31-8.

COMMENTARY

This paper is an excellent update of Arseni's report from 1960 and Arce's review of 1985, concerning the surgical treatment of thoracic disc herniation. The big achievements in the management of this disease are well documented and analyzed in this report. It is the first publication demonstrating in a retrospective analysis that the results obtained with the transthoracic approach are superior to those obtained with other techniques. Our results obtained in 38 cases of thoracic disc herniation treated over

the past 12 years (either using the transthoracic approach or microsurgical endoscopy) are similar to those reported in Mulier's review. The biggest advantage of the anterior approach is that it respects the posterior structures, avoiding unnecessary bone, muscle, or nerve removal. Our experience with microsurgical endoscopy in more than 35 cases treated for different pathologies shows that with improved instruments and sufficient technical skill, any disc herniation located between T2 and L1 can be removed safely. By changing the site of insertion of the trocar, mobilization of the scapula or splitting of the diaphragm can be avoided as well.

Early diagnosis and refined surgical techniques will lead to further improvements in the treatment of thoracic disc herniations.

Daniel Rosenthal, M.D.

*Klinik für Neurochirurgie
Johann Wolfgang Goethe-Universität
Frankfurt, Germany*

Mulier et al have completed a thorough review of the management of thoracic disc herniations. It is not surprising that the transthoracic approach, like anterior cervical surgery, proved superior both as a primary and secondary procedure to other routes for dealing with predominantly ventral pathology. I would add that the actual pathology encountered in both regions is probably comparable to many so-called discs or spondylotic bars actually consisting of ossification of the posterior longitudinal ligament (OPLL). In fact, in this manuscript, when discs were found to "extend to and through the dura," they likely consisted of OPLL and were not disc herniations at all. Furthermore, the "two disc herniations which recurred at the same level following original posterolateral approaches" may have represented incompletely resected OPLL masses. Finally, when the "transthoracic route was recommended to excise intradural herniations as well as multiple herniations as a trend toward better results was noted," this sounds classic for continuous OPLL rather than discal/spondylotic pathology. Here, I agree with the authors' recommendation that patients, particularly those who have failed first procedures, be evaluated with computed tomography-myelography studies as the detail regarding "residual or new pathology" is so much better than that provided by MR or even non-contrast computed tomography examinations. In the Japanese literature, 10% of OPLL is located in the thoracic spine, while recent experience with a North American series of 26 patients with ossification of the spinal ligaments re-

vealed a 0.3% frequency of thoracic OPLL [submitted for publication].

I commend these authors on the thoroughness of their review, and would again underscore their conclusion that the transthoracic technique which provides optimal visualization of both anterior and anterolateral pathology be used to resect thoracic discs or spondylosis that may actually prove to be OPLL.

Nancy E. Epstein, M.D., FACS

*Neurosurgeon
New Hyde Park, New York*

The authors are to be congratulated on their thoughtful review of an uncommon, but clinically important problem. Certainly one valuable piece of information that impacts on the clinician treating thoracic disc herniation is the recognition that recovery is more a function of the length of time the patient has been myelopathic than the specific location of the disc.

They have not provided us, however, absolute indications for surgery. It has become popular in some circles to operate on patients with purely axial pain and evidence of thoracic disc degeneration or bulging; this effort suggests that this is not acceptable—a finding with which most neurosurgeons would agree. The promising technique of thoracoscopy and microsurgical endoscopic resection of thoracic discs may revise how we look at the thoracic spine, particularly for those who have historically used transthoracic procedures.

The authors' determination of complication rates is inaccurate, at least for the lateral extracavitary approach. We have used the extracavitary approach to the thoracic spine in over 400 instances in the last 10 years, including 36 for disc herniation. We have seen unintentional intercostal nerve injury in less than 1%. The pulmonary complication rate (primarily pleural tears requiring a chest tube) is 3% in a series that includes trauma and tumors. Obviously, then, at least the short-term morbidity is much less. Similarly, the morbidity they report for thoracotomy is less than that reported elsewhere.

Caution is also advised in the statistical interpretation of the collected cases. Unfortunately, criteria for identifying myelopathy and improvement are, at best, difficult to interpret. Application of statistics to heterogeneous retrospective reviews is generally next to impossible.

Again, the authors are to be thanked for their careful and thoughtful review. Efforts for a multicenter surgical trial that includes microendoscopy are pending, and should provide additional infor-

mation for the clinician. Until then, this review represents a genuine contribution.

Dennis J. Maiman, M.D.
*Department of Neurosurgery
Medical College of Wisconsin
Milwaukee, Wisconsin*

Thoracic disc herniations are rare, but the incidence is increasing with the advent of magnetic resonance imaging. Selection of the surgical approach to a herniated thoracic disc is worth serious consideration. Drs. Mulier and Debois did an extensive review of the literature to compare the results of various surgical approaches, and to determine the optimal approach for treating thoracic disc herniations. Considering the anatomy and pathophys-

iology of thoracic disc herniations, the transpleural transthoracic approach is the most reasonable choice. It provides a wide angle of view for the surgeon, and the posterior half of the vertebral body and herniated disc can be removed safely under direct vision. This approach, as the authors point out, is not practical for disc herniations above the T4 level, and carries a substantial risk of pulmonary complications. Another limitation of this procedure occurs with discs herniated to the left side, because the heart and great vessels hinder the approach.

Kyu Chang Lee, M.D.
*Department of Neurosurgery
Yonsei University College of Medicine
Seoul, Korea*

Considerable education is needed to increase the public awareness of warning signs and risk factors for stroke, and those at the greatest risk for the potentially deadly illness are the least knowledgeable, according to an article in the April 22 stroke theme issue of the *Journal of the American Medical Association* (JAMA).

Arthur M. Pancioli, M.D., and colleagues at the University of Cincinnati in Ohio surveyed 1,880 people in the Greater Cincinnati Metropolitan area to assess current public knowledge of stroke warning signs and risk factors.

The researchers found that only slightly more than half of the respondents (57 percent) correctly identified at least one of five established warning signs for stroke, and substantially fewer people could name more than one warning sign. Only about two-thirds of respondents (68 percent) were able to name at least one of the established risk factors for stroke. Also, those aged 75 or older, who are at the greatest risk for stroke, were the least knowledgeable about stroke warning signs and risk factors, according to the researchers.

For the study, the researchers used the stroke warning signs established by the National Institute of Neurological Disorders and Stroke:

- Sudden weakness or numbness of the face, arm, or leg
- Sudden dimness or loss of vision, particularly in one eye
- Sudden difficulty speaking or understanding speech
- Sudden severe headache with no known cause
- Unexplained dizziness, unsteadiness or sudden falls

The researchers also found that those who possessed one of the established risk factors for stroke (high blood pressure, diabetes, or smoking) often did not know that their conditions were risk factors. Groups at the greatest risk . . . were the least knowledgeable about stroke.

—AMA PRESS RELEASE
APRIL 21, 1998

Current address of Stefaan Mulier :

Stefaan Mulier, MD

Philipslaan 66

3000 Leuven

Belgium

+32 16 35 67 86

+32 498 78 73 57

stefaan.mulier@skynet.be

<http://drmulier.com/research.html>